

## Case Report



## Simultaneous Infection in a Buffalo calf with *Toxocara vitulorum* and *Eimeria bareillyi*: A Case Report

PREM SAGAR MAURYA, SHIVANI SAHU\*, SHRIYA RAWAT, VIKAS JAISWAL

College of Veterinary and Animal Sciences, Sardar Vallabhbhai Patel University of Agriculture & Technology- 250110, Meerut, U.P., India.

**Abstract** | 2 months old female buffalo calf suffering from blood tinged, foetid, mud-coloured diarrhea infected simultaneously with *Toxocara vitulorum* and *Eimeria bareillyi* was treated with Piperazine hexahydrate @ 300mg/kg body weight along with Amprolium@10mg/kg body weight orally daily for five days for its complete recovery. This is the first report, in the region of Meerut, Western Uttar Pradesh.

**Keywords** | Buffalo calf, Toxocarosis, *Eimeria bareillyi*, Meerut, Western Uttar Pradesh.

**Editor** | Muhammad Abubakar, National Veterinary Laboratories, Islamabad, Pakistan.

**Received** | March 04, 2019; **Accepted** | August 25, 2019; **Published** | March 05, 2020

\***Correspondence** | Shivani Sahu, College of Veterinary and Animal Sciences, Sardar Vallabhbhai Patel University of Agriculture & Technology- 250110, Meerut, U.P., India; **Email:** shivanisahu010@gmail.com

**Citation** | Maurya PS, Sahu S, Rawat S, Jaiswal V (2020). Simultaneous Infection in a Buffalo calf with *Toxocara vitulorum* and *Eimeria bareillyi*: A Case Report. Res. J. Vet. Pract. 8(1): 1-3.

**DOI** | <http://dx.doi.org/10.17582/journal.rjvp/2020/8.1.1.3>

**ISSN (Online)** | 2308-2798

**Copyright** © 2020 Sahu et al. This is an open access article distributed under the Creative Commons Attribution License, which permits unrestricted use, distribution, and reproduction in any medium, provided the original work is properly cited.

### INTRODUCTION

Indian economy is mainly agricultural based, out of which livestock sector is an integral component. The buffaloes in India constitute about 57% of world's population and contribute towards milk, meat and hide production. Toxocarosis is a common cause of calf-hood mortality in India (Radiostits et al., 2000). It is caused by *Toxocara vitulorum* which occurs in the small intestine of Indian buffaloes below three months of age, especially in tropical and subtropical countries (Raza et al., 2013). Prenatal/placental and transmammmary/ transcolostral route constitutes the major source of infection for calves (Wickramasinghe et al., 2009). *T. vitulorum* is amongst the most destructive parasites of young calves, the larvae of which undergo migration causing great damage to several organs, especially to the liver and the intestine and is frequently manifested by diarrhea, poor performance and poor growth rate (Ahmed et al., 2016). Coccidiosis is an important cause of neonatal mortality in livestock, including buffalo. More than 12 species of *Eimeria* are reported in buffalo, but *Eimeria bareillyi* is the most pathogenic (Dubey, 2018). Coccidiosis mostly affects young animals and sometimes,

morbidity can reach up to 100% (Faber et al., 2002). The infection is characterized by acute invasion and destruction of intestinal mucosa, anorexia, weight loss, diarrhoea, emaciation and sometimes even death (Coetzer and Justin, 2004). Calves with low immunity and poor nutrition are more vulnerable for such infections (Starke-Buzetti, 2006).

### MATERIALS AND METHOD

A two month old female buffalo calf was presented to OPD section, College of Veterinary and Animal Sciences, Sardar Vallabhbhai Patel University of Agriculture & Technology, Meerut with a history of diarrhea, poor-growth and loss of appetite since 3–5 days. On physical examination of faeces it was found to foul smell like butyric acid, mud-coloured, blood tinged with presence of mucus flakes.

The faecal sample was screened for any parasitic eggs, cyst or oocyst. The species of *Eimeria* was further confirmed by culturing faecal sample in 2.5% potassium dichromate at 37°C for 3 days. Aeration with the help of a pasteur pipette and rubber bulb was done regularly to supply oxygen to the oocyst. A drop of the suspension was examined microscop-

ically to check complete sporulation.

## RESULT

On direct faecal examination by following standard protocols (Soulsby, 1982) we found the eggs of *Toxocara vitulorum* and oocyst of *Eimeria bareillyi* in the same microscopic field (Figure 1). The eggs of *Toxocara vitulorum* are subglobular, provided with a finely pitted albuminous layer and measures 75-95 by 60-75  $\mu\text{m}$  (Figure 2). Oocyst of *Eimeria bareillyi* is pyriform in shape with the narrow anterior end having slightly flattened surface, measuring 28 x 19  $\mu\text{m}$  in size (Figure 3). On sporulation typical oocysts/sporocyst of *Eimeria bareillyi* were found under microscope having four sporocysts, each containing two sporozoites (Figure 4).

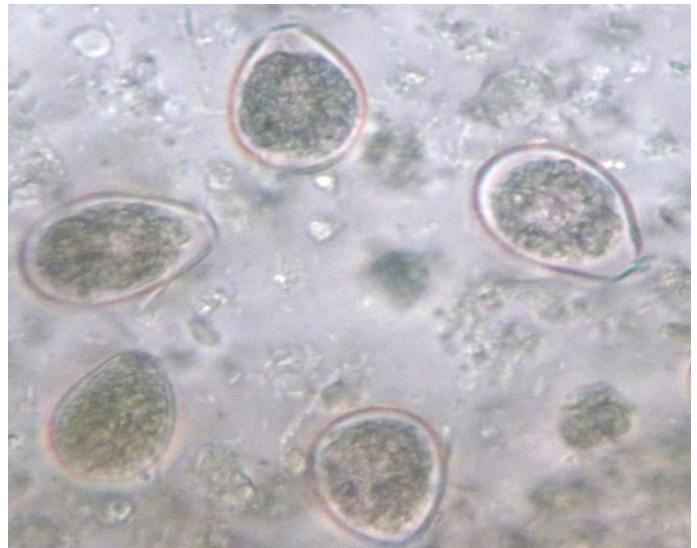


Figure 3: Oocysts of *Eimeria*

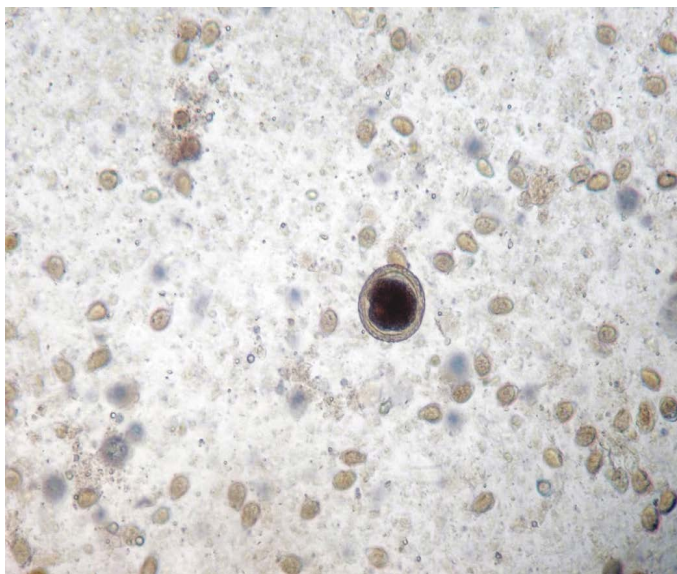


Figure 1: Egg of *Toxocara vitulorum* and Oocysts of *Eimeria bareillyi* (10x)

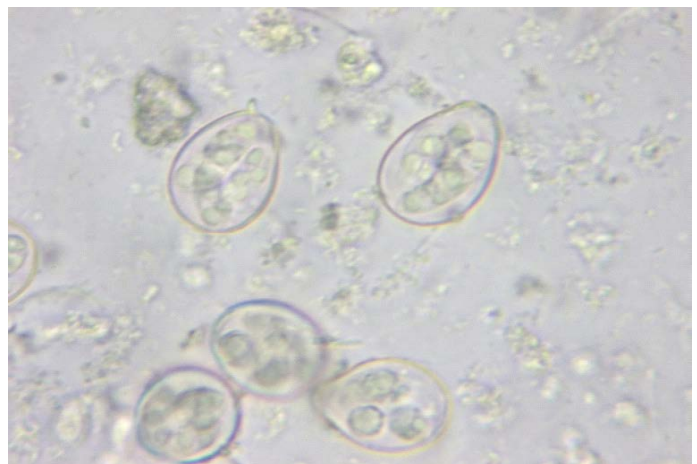

Figure 4: Sporulated Oocysts of *Eimeria bareillyi* (40x)

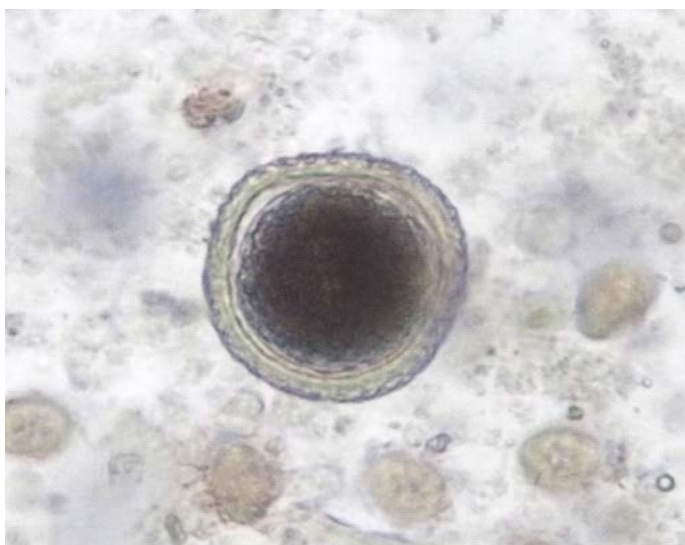


Figure 2: *Toxocara vitulorum* egg

## TREATMENT

Therefore, to ameliorate the symptoms the calf was treated with Piperazine hexahydrate @ 300mg/kg body weight along with Amprolium@10mg/kg body weight orally daily for five days for its complete recovery. As a measure of supportive therapy we administrated 1ml of Tribivet (Intas Pharmaceuticals) intra muscularly. Dextrose normal saline (DNS) @5 ml/kg body weight and Ringer's lactate (RL) @5 ml/kg body weight were given intravenously along with multivitamin preparation (Conciplex@ 3ml) to prevent dehydration and to maintain electrolyte imbalance. The fecal sample was again examined 10 days post treatment under 10X for three times to assure complete recovery of the calf, which was found to be negative.

## DISCUSSION

*Eimeria bareillyi*, a cause of coccidiosis in Indian water buffalo calves is slight to moderately pathogenic (Sanyal et al., 1985). Young calves are more susceptible to *Toxo-*

*cara vitulorum* infection and coccidiosis than adults, owing to placental or colostrum infection from dam and in latter case due to their low immunity. It causes severe enteritis resulting in diarrhea, dysentery and dehydration. Inadequate feeding of colostrum, exposure to contaminated environment, underfeeding and poor sanitation are some of the predisposing factors (Yadav and Sharma, 1986). Thus, deworming of young calves should be done at 3-6 weeks of age in order to reduce dissemination of eggs, hence decreasing soil contamination. Enhancing immunity of calves by proper colostrum feeding and prevention of infection from contaminated feed or fodder are the important steps for controlling the disease (Avcioglu and Balkaya, 2011). Piperazine showed 100% efficacy against toxocarosis which was in agreement with our present report (Rao et al., 2000). The amprolium has both therapeutic and prophylactic effects against coccidiosis in livestock (Radiostits et al., 2010).

## CONCLUSION

Our present study have reported the simultaneous infection of calf with *Toxocara vitulorum* and *Eimeria bareillyi*, which will be helpful in devising suitable control strategies like deworming of the dam in the third trimester with fenbendazole, feeding the calves with milk replacer, as transcolostral transmission, being the main cause. Proper managemental practices like good nutrition, sanitation and hygiene are the key to success over these problems.

## ACKNOWLEDGMENTS

The authors are thankful to the Dean, College of Veterinary and Animal Sciences, Sardar Vallabhbhai Patel University of Agriculture and Technology, Meerut for providing the facilities needed for carrying out this work.

## CONFLICT OF INTEREST

The authors declare that there is no conflict of interest.

## AUTHORS CONTRIBUTION

All authors were equally involved in processing, identification, photography of parasites and help in writing of manuscript.

- Ahmed R, Wani Z, Allaie I, Bushra M, Hussain H (2016). *Toxocara vitulorum* in a suckling calf: a case study. J. Parasit. Dis. 40: 1330-1331. <https://doi.org/10.1007/s12639-015-0682-0>
- Avcioglu H, Balkaya I (2011). A comparison of the efficacy of subcutaneously administered ivermectin, doramectin, and moxidectin against naturally infected *Toxocara vitulorum* in calves. Trop. Anim. Health Prod. 43:1097-1099. <https://doi.org/10.1007/s11250-011-9807-3>
- Coetzer, J and Justin R (2004). Infectious Diseases of Livestock. (2nd edn.), Oxford University Press.
- Dubey JP (2018). Re-evaluation of endogenous development of *Eimeria bareillyi* Gill, Chhabra and Lall, 1963 in water buffalo (*Bubalus bubalis*). Parasitology. 145(14): 1845-1852 <https://doi.org/10.1017/S0031182018000604>
- Faber JE, Kollmann D, Heise A, Bauer C, Failing K, Burger HJ, Zahner H (2002). *Eimeria* infections in cows in the periparturient phase and their calves: oocyst excretion and levels of specific serum and colostrum antibodies. Vet. Parasitol. 104:1-17. [https://doi.org/10.1016/S0304-4017\(01\)00610-0](https://doi.org/10.1016/S0304-4017(01)00610-0)
- Radiostits OM, Gay CC, Blood DC, Hinchcliff KW (2000). Veterinary medicine, 9th edn. W.B. Saunders Co., New York.
- Radiostits OM, Gay CC, Hinchcliff KW, Constable PD (2010.) Veterinary medicine. A textbook of the diseases of cattle, horse, sheep, pigs, and goats, 10th edn. Bailliere Tindall, London, 1498-1506.
- Rao RS, Kumar MU, Rao R (2000). Therapeutic trial of drugs in ascariasis in buffalo calves. Indian Vet. J. 77:57-59
- Raza M, Murtaza S, Ayaz M, Akhtar S, Arshad H, Basit A, Bachaya HA, Ali M, Khan MI (2013). *Toxocara vitulorum* infestation and associated risk factors in cattle and buffalo at Multan district, Pakistan. Science International (Lahore). 25: 291-294.
- Sanyal P K, Ruprah N S, Chhabra MB (1985). Evidence of cell mediated immune response in infection with *Eimeria bareillyi* in buffaloes. Vet. Parasitol. 17: 111-115. [https://doi.org/10.1016/0304-4017\(85\)90096-2](https://doi.org/10.1016/0304-4017(85)90096-2)
- Soulsby, E.J.L (1982). Helminths, Arthropods and the Protozoa of Domesticated Animals, 7th edn, Bailliere Tindall, An imprint of Elsevier 110 Greycoat Place, London SW1P1SB. 155, 169, 765-66.
- Starke-Buzetti WA (2006). *Toxocara*- The Enigmatic Parasite. CABI publishing, CAB International, 260-277.
- Wickramasinghe S, Yatawara L, Rajapakse RPVJ, Agatsuma T (2009). *Toxocara vitulorum* (Ascaridida: Nematoda): mitochondrial gene content, arrangement and composition compared with other *Toxocara* species. Mol. Biochem. Parasitol. 166: 89-92. <https://doi.org/10.1016/j.molbiopara.2009.02.012>
- Yadav BS and Sharma DN (1986). Morbidity and mortality in buffalo (*Bos bubalis*) calves. Indian Vet. Med. J. 10: 219-223.