



Evaluation of Osteopontin Expression in Liver and Colon of Murine Schistosomiasis *mansoni* Model: A Pathological and Immunohistochemical Study

HEND MOHAMED HUSSEIN^{1*}, NEHAL A RADWAN², NOHA ABDELFATTAH ELLEBOUDY^{1*}, REHAM FATHY TASH³, YOUSSEF SHOUKRY³, AHMED H ABDELAZEEM^{4,5}, SHIMAA ABDELRAOUF ELGOHARY²

¹Department of Parasitology, Faculty of Medicine, Ain Shams University, Cairo 11591, Egypt; ²Department of Pathology, Faculty of Medicine, Ain Shams University, Cairo 11591, Egypt; ³Department of Anatomy, Faculty of Medicine, Ain Shams University, Cairo 11591, Egypt; ⁴Department of Medicinal Chemistry, Faculty of pharmacy, Beni-Suef University, Beni-Suef 62514, Egypt; ⁵Department of Pharmaceutical Sciences, College of Pharmacy, Riyadh Elm University, Riyadh 11681, Saudi Arabia.

Abstract | Osteopontin is a granulomatogenic chemokine considered to be an inflammatory progenitor suggested to participate in hepatopathology in schistosomiasis. The aim of the current study is to evaluate Osteopontin immunohistochemical expression in chronic murine *Schistosoma mansoni* infection through week 7 till week 23 in both liver and colon histopathology samples, correlating them to serum glutamic-oxaloacetic transaminase and glutamate pyruvate transaminase levels. The results revealed significant association between levels of SGOT and SGPT and percentage of liver inflammation (P = 0.037 and 0.002 respectively), also smaller and bigger sized granulomas were significantly linked to low level of SGPT (P = 0.005). A parallel histopathologic change over time was detected in both liver and colon specimens. The infected groups show acute granuloma formation associated with liver fibrosis from week 7 through week 23. Changes in the expression of Osteopontin was observed at week 7. Upregulated expression was strongly seen from week 11 to week 13. At week 13 to week 17 the fibrotic granulomas reveal many positive cells, from week 21 to week 23 the expression was weak and almost was returned to near normal levels. Intensity of the expression was positively significantly correlated with the degree of inflammation, granuloma size and the degree of fibrosis (P < 0.01). This study highlights the use of OPN as a potential diagnostic marker of liver injury and the probability of using an anti OPN in early chronicity stage to prevent schistosomal subsequent pathological changes.

Keywords | *Schistosoma mansoni*, Osteopontin, Granuloma, Liver fibrosis, Colon.

Received | October 14, 2020; **Accepted** | December 12, 2020; **Published** | June 15, 2021

***Correspondence** | Hend Mohamed Hussein, Noha Abdelfattah Elleboudy, Department of Parasitology, Faculty of Medicine, Ain Shams University, Cairo 11591, Egypt; **Email:** D.hend_m@yahoo.com, drnoha_elleboudy@med.asu.edu.eg

Citation | Hussein HM, Radwan NA, Elleboudy NA, Tash RF, Shoukry Y, Abdelazeem AH, Elgohary SA (2021). Evaluation of osteopontin expression in liver and colon of murine schistosomiasis *mansoni* model: a pathological and immunohistochemical study. Adv. Anim. Vet. Sci. 9(7): 1078-1086.

DOI | <http://dx.doi.org/10.17582/journal.aavs/2021/9.7.1078.1086>

ISSN (Online) | 2307-8316; **ISSN (Print)** | 2309-3331

Copyright © 2021 Hussein et al. This is an open access article distributed under the Creative Commons Attribution License, which permits unrestricted use, distribution, and reproduction in any medium, provided the original work is properly cited.

INTRODUCTION

Schistosomiasis has been considered by the World Health Organization (WHO) as one of the neglected Infectious diseases (NIDs). Schistosomiasis is an important public health problem and presents an economic burden since a review of the disease burden estimated that more than 200 000 deaths per year in sub-Saharan Africa.

There is approximately 779 million people are at risk of infection worldwide. The Global Health Estimates disease burden over the past decade from 1.7 million disability-adjusted life years (DALYs) to as many as 56 million DALYs, depending on the disease prevalence (Hotez et al., 2014; WHO, 2016; Naghavi, 2017).

Three major species of *Schistosoma* are endemic and leads

to human disease; *Schistosoma mansoni* (*S. mansoni*) in Africa, the Middle East, and South America, *Schistosoma japonicum* (*S. japonicum*) common in Southeast Asia, and *Schistosoma haematobium* (*S. haematobium*) mainly in Africa and the Middle East (Gryseels et al., 2006).

In Egypt, although there is decline in prevalence rates of schistosomiasis mansoni but there are still several recent surveys that report it in different areas (Elmorshedy et al., 2020). Reports associate schistosomiasis mansoni with 20.8% of colonic cases (Sabry et al., 2015), and with 26.7% of hepatocellular carcinoma patients (Gad et al., 2011).

Osteopontin (OPN) as an extracellular matrix acidic-glycophosphoprotein expressed by several cell types binds to CD44 to mediate many biological and immunological processes (Matsue et al., 2015; Cabiati et al., 2017). OPN can also induce inflammation (Kelly et al., 2005; Naldini et al., 2006). It encourages tissue remodeling, upregulate fibrosis, and help in angiogenesis (El-Asrar et al., 2012).

Osteopontin was suggested to be a better marker to follow up the prognosis of hepatocellular carcinoma (HCC) in its early stages of development than alpha-fetoprotein (AFP) (Shang et al., 2012).

The aim of this study was to evaluate the dynamics of OPN expression in chronic murine *Schistosoma mansoni* infection through week 7 till week 23 in both liver and colon histopathology samples.

MATERIAL AND METHODS

EXPERIMENTAL ANIMALS

Fifty wiss albino female CD-1 six weeks old mice with average weight of 20 g, were bred and maintained at Theodor Bilharz Research Institute, the experimental animal research unit of the Biological Supply Unit at, Giza, Egypt. Following the U.S. Public Health Service Policy on the Use of Laboratory Animals for animal experimentation and in accordance with the ethical committee of Faculty of medicine Ain Shams University animal care protocol. With; air-conditioned room at 21°C in a 12-h light/dark cycle, 50 % humidity, and free access to standard commercial pelleted diet and water. Another fifty mice same weight and age were used as a matching control.

SCHISTOSOMA MANSONI INFECTION

At Theodor Bilharz Research Institute, *S. mansoni* Egyptian strain cercariae were provided by the Malacology Lab of the Schistosomiasis Unit. Subcutaneous infection was performed using freshly shed 80 *S. mansoni* cercariae to each mouse through abdominal exposure in non-chlorinated water for 20 min. Confirmation of infection was by

finding *S. mansoni* eggs in mice stool.

STUDY GROUPS AND ASSAYED PARAMETERS

At 7, 9, 11, 13, 15, 17, 19, 21 and 23 weeks after infection, 5 mice were randomly selected and sacrificed. Blood samples collected during sacrificing the mice. Liver and colon samples were collected for further studies. To obtain the schistosomes and worm count; portal perfusion was performed according to Pellegrino and Siqueira (1956). A control of matching weight and age were processed in the same way. Biochemical assays: were used for glutamic-oxaloacetic transaminase (SGOT) or Aspartate transaminase (AST) and glutamate pyruvate transaminase (SGPT) or Alanine aminotransferase (ALT) assay by commercial assay kit (Spinreact, S. A. Ctra. Santa Coloma, Spain). (Young, 2001) by (UniCel® Dx C 800 Synchron® Clinical System (Beckman Coulter GmbH). According to the manufacturer instructions.

To obtain the schistosomes and worm count; portal perfusion was performed according to Pellegrino and Siqueira (1956).

HISTOPATHOLOGICAL STUDY

Liver specimens were obtained, and the distal 3 cm of the colon was cut and washed with saline. They were fixed in 10% formalin and graded alcohol series were used to dehydrate the specimens. The specimens were then treated with xylene and embedded in paraffin blocks. The blocks were cut into 5- μ m thick sections, and serial sections were placed on glass slides. Then according to standard procedures, the sections were stained with hematoxylin and eosin (H&E) and Masson trichrome (MT) according to Bancroft and Gamble (2008).

To evaluate and assess liver and large intestinal histopathological changes, two pathologists examined 10 different low-power fields of H&E and MT-stained sections (selected fields were in almost the same location) for each mouse (Chen et al., 2011). Histopathological score in these sections was determined according to Warren et al. (1975) & Ashour et al. (2015) with modifications. The degree of inflammation was scored from (0 to 3+). In addition, an ocular micrometer is used to measure the dimensions of non-confluent granulomas containing eggs in their centers at a magnification of 100 \times (Lichtenberg, 1962). Granuloma dimension = maximum width \times maximum length. Mean granuloma dimension of each section equal the sum of all granuloma dimensions in each section divided on the number of granulomas in each section. Furthermore, each MT-stained section was examined at 100 \times magnification to evaluate the degree of liver fibrosis. The degree of fibrosis was scored in each section based on (0 to 3+) (Warren et al., 1975).

Table 1: Descriptive statistics of parasitological parameters and liver function test

	Number	Median	Minimum	Maximum	Percentile	
					25%	75%
SGOT IU/L	60	321.5	172	453	248.5	388
SGPT IU/L	60	69.5	10	310	40	84
Male worms count	54	1.5	0	6	1	3
Female worms count	54	1	0	7	0	2.25
Copula count	54	3	0	4	2	3

IMMUNOHISTOCHEMICAL STUDY

Immunohistochemical (IHC) staining for OPN was conducted on sections 5µm thickness using an automated immunostainer (Roche Ventana, BenchMark ULTRA system) according to the manufacturer’s instructions primary antibody incubation against mouse monoclonal anti-Osteopontin antibody (1:200 dilution; clone sc-21742 Santa Cruz Biotechnology).

The immunoreactivity of OPN was evaluated and OPN expression was scored according to Ito et al. (2006) and Higashiyama et al. (2017) as follows: negative (0); weak or focal expression (1+); moderate expression with focal strong expression (2+); and strong expression (3+). OPN expression is detected in the cytoplasm of the granuloma macrophages (O’Regan et al., 2001).

Evaluation of OPN expression was done by two pathologists without any prior information about each specimen. When different grades were assigned, the final agreement was obtained after careful review of the slides by multi-headed microscope session for adjustment of the inter-observer controversy.

STATISTICAL ANALYSIS

Statistical analysis for different variables was done by IBM SPSS statistics (V. 24.0, IBM Corp., USA, 2016) was used. For descriptive data analysis of quantitative variables, the median, minimum and maximum were used. For description of qualitative variables were presented as number and percentage. Chi-square test was used to compare qualitative variables. (Plackett, 1983) P value ≤ 0.05 is considered significant, while p value of <0.001: highly significant (HS).

Stacked bar graph were used to depict numeric values across multiple categorical variables (Der and Everitt, 2014).

RESULTS

PARASITOLOGICAL AND BIOCHEMICAL PARAMETERS

Parasitological parameters and liver functions tests descriptive statistics along the studied weeks are shown in Table 1.

SGOT levels were categorized into low (172-322 IU/L) and (323-453 IU/L) as high. While SGPT levels were set to low (10-70 IU/L) and high (71-310 IU/L). Graph stacking of the biochemical results were presented in stacked bar chart (Plate 1), to study their changes in relation to liver OPN expression, fibrosis, inflammation, and granuloma size using Pearson Chi-square test. Liver OPN expression in relation to changes in both SGOT and SGPT levels showed inverse association in high levels and the reverse with their low values (Plate 1a) (P =0 .545 and 0.144 respectively).

Concerning the percentage of liver inflammation also an inverse association with high SGOT and SGPT levels (P =0 .037 and 0.002 respectively) was detected. As high levels of SGOT and SGPT were found among cases with mild inflammatory intensity (Plate 1b).

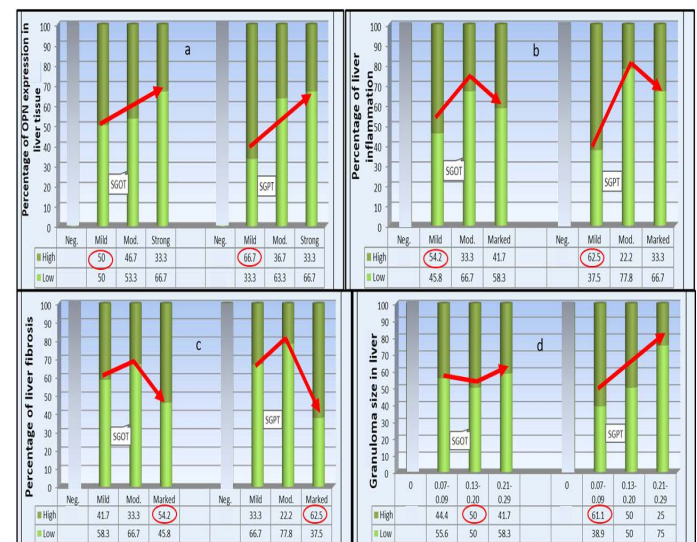


Plate (1): Effect of changes in SGOT and SGPT levels on liver pathological parameters

SGOT and SGPT serum levels show a. Non-significant inverse association with the degree of OPN expression -b. Significant inverse association with the percentage of liver inflammation -c. Significant association with liver fibrosis-d. Non-significant association SGOT with liver granuloma size while significant for SGPT by Pearson Chi-Square (P < 0.05). The highest percentage of all categories are circled.

	H&E	Masson trichrome	OPN	Comment		H&E	Masson trichrome	OPN	Comment
Control				Normal morphology	W13				The predominant feature of granulomas was increased fibrosis forming the typical chronic granulomas with significant decrease in the number of other inflammatory cells.
W7				Aggregation of inflammatory cells around the Schistosoma eggs with subsequent formation of granulomas mainly in portal areas	W21				Granulomas were markedly reduced in size and the ova became degenerated and fibrosis
W9				The quantity of inflammatory cells and the granuloma size increased. Fibrosis appeared at the periphery of the granulomas and collagen fibers became longer and thicker.	W23				was more stable. In the large intestinal specimens, the major tissue reaction to ova was in the submucosa in the form of acute inflammatory foci, whereas granulomas formation collagen fibers were present mainly along the periphery of the granulomas
W11				The granulomas reached maximum size and quantity, they were formed of numerous inflammatory cells such as macrophages, lymphocytes and eosinophils with excess collagen fibers wrapped and stretched within the granulomas.					

Plate (2): Photomicrograph of the mice liver

Photomicrograph of the mice liver showing the normal group (control) architecture while the infected group showed typical schistosomal hepatopathological characteristics with granuloma formation associated with subsequent fibrosis from week 7 through week 23. (H&E x100, Masson trichrome X 100, Anti Osteopontin Ab OPN X 100).

While stratification against liver fibrosis score was significant ($P=0.037$) for SGOT and for SGPT ($P=0.002$) with highest serum levels among those with marked fibrosis. Finally, the difference in liver granuloma size was non-significantly associated with serum level of SGOT ($P=0.076$) whereas for SGPT levels; got inverse significant link to the granulomas size and the reverse regarding its low level ($P=0.005$).

HISTOPATHOLOGICAL RESULTS

Typical schistosomal pathology was presented up on staining with both H&E and MT in both liver and colon samples starting from the 7th week till the 23rd expressed in (Plates 2 & 3) with similar changes over time with the percentage of fibrosis and the granuloma dimensions.

IMMUNOCYTOCHEMICAL RESULTS

Highly significant adjoined variation of OPN intensity

	H&E	Masson trichrome	OPN	Comment
W11				A major tissue reaction to ova in the mucosa with acute inflammatory foci, whereas granulomas characterized the response in the submucosa. Ova and related reactions in the muscular and subserosal layers. The collagen fibers were only interspersed among the periphery of the granulomas
W21				

Plate (3): Photomicrograph of the mice colon
Photomicrograph of the mice colon of the infected group at week 11 and 21. (H&E x100, Masson trichrome X 100, Anti Osteopontin Ab OPN X 100).

with *S. mansoni* infection along the studied weeks of infection was detected by Pearson Chi-square test for liver (150.000, P=0.0001) and colon (162.660, P=0.0001). Mostly no staining was demonstrated in the normal control group). At week 7 in the model group, the area of inflammatory cell infiltration shows wide distribution of positively stained cells, forming acute granulomas. Upregulated expression of OPN expression was strongly seen from week 11 to week 13.

Many compactly stained positive cells surround and infiltrate into the granulomas, are mainly accumulated in the fibrotic areas, and along the fibrous strands.

At week 13 to week 17 the fibrotic granulomas reveal many positive cells which are distributed and dispersed mainly at its periphery of granulomas. However, from week 21 to week 23 OPN expression was weak and almost was returned to near normal levels as shown in (plates 2&3, right column).

STATISTICAL ANALYSIS

Statistical analysis revealed that intensity of OPN expression was significantly associated with the degree of liver

inflammation; The highest present of negative OPN intensity was found among no inflammatory cases; while the highest present of mild OPN intensity (n=12) was found among those with mild inflammatory cases, among those moderate OPN intensity (n=30); the highest percent was found among those mild and moderate inflammatory cases; while those strong OPN intensity (n=6); the highest percent was found among those moderate inflammatory cases (p<0.001, HS) (Plate 4-a).

As for the granuloma size the highest percent of cases with negative OPN intensity (n=12); was found among those without granuloma cases; while the highest present of mild OPN intensity the highest percent was found among those 0.07-0.09 granuloma size; among those moderate OPN intensity (n=30); the highest percent was found among those 0.21-0.29 granuloma size while those strong OPN intensity (n=6); the highest percent was found among those 0.21-0.29 granuloma size (p <0.001, HS) (Plate 4-b). Finally, regarding the degree of fibrosis the highest percent of cases with negative OPN intensity (n=12); was found among those fibrosis score 0 cases; while the highest present of mild OPN intensity (n=12); was found among those marked fibrosis score; among those moderate (n=30); the highest percent was found among those moderate, and marked fibrosis score while those with strong OPN intensity (n=6); the highest percent was found among those marked fibrosis score (p<0.001, HS) (Plate 4-c). The association of OPN expression percentages in liver and colon samples were also significant where, highest percentage among liver samples (n=60) were with moderate expression whereas, in colon samples (n=59) the highest percentage with mild expression (Plate 4-d).

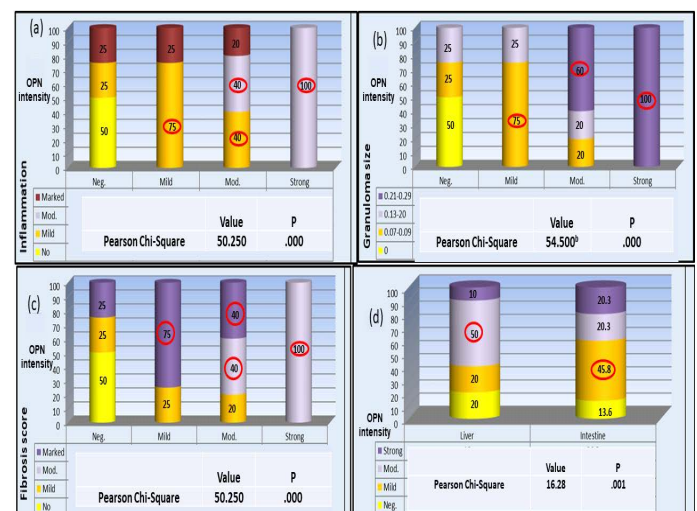


Plate (4): OPN percentage of expression in association with liver pathology variables a- inflammation b- Granuloma size c- Fibrosis score. d- Variation of OPN expression pattern between liver and colon samples. The highest percentage of all categories are circled. Pearson Chi-square test in all results were significant P < 0.05

OPN role in liver diseases was discussed in several studies focusing on its role as inflammatory progenitor and macrophage/neutrophils attractant. In hepatitis, hepatocellular and colorectal carcinomas special emphasis on its potentiality as a diagnostic and prognostic biomarker was mentioned (Agrawal et al., 2002; Rohde et al., 2007; Likui et al., 2010; Shang et al., 2012; Wen et al., 2016). OPN plays a leading role in granuloma formation and progression of fibrosis (Morimoto et al., 2004; Wang et al., 2014; Coombes et al., 2015). OPN can binds with receptors as CD44, α v integrin, vimentin, estrogen-related receptor alpha and MYD88 inducing infiltration, migration, invasion, and metastasis of cells (Boudjadi, et al., 2013; Wen et al., 2016).

Switching of the host response from Th1 to Th2-mediated response occurs around six to eight weeks post infection. With the stage of egg deposition, soluble egg antigen triggers the granulomatous inflammatory response (Colley et al., 2014). As schistosomal pathology does not affect liver cells (Lambertucci et al., 2014), so no changes in serum transaminases levels are expected in early cases (Sherwood et al., 2014). The studied enzymes showed significant association with the severity of fibrosis in agreement with Camacho-Lobato et al. (1998) and Leite et al. (2013). This could be attributed to the progress of fibrosis affecting liver function and leading to these changes. In this study levels of transaminases were significantly negatively related to both the level of liver inflammation and level of OPN expression in contrast to Tang et al. (2020) who detected increase in SGPT with liver inflammation along with increase OPN expression. That is may be credited to the difference in the etiological origin of the liver condition between both studies.

In the current study, typical colonic and hepatopathological changes were induced in *S. mansoni*-infected animals and Osteopontin immunohistochemical expression displayed a strong correlation with pathologic changes in the liver and colon. OPN levels were up regulated by schistosomiasis and positively correlated with the degree of fibrosis in the liver as detected by Chen et al. (2011) who studied week6 till week18. With peaking levels in week 10 then declining by week 18. This goes with the dynamics of OPN expression achieved from this study from week7 till week 13 where peaking occurred then declining happened. Pereira et al. (2015) also had similar results in OPN expression in week16 compared to week6 post infection. Science the aforementioned study was only limited to two readings and no variation in the degree of expression was studied, no available data could be compared to ours as we choose a longer course of infection leading to a decline in OPN expression overtime. When the state of immune in-

ertia is reached as the period of late chronicity develops (Hams et al., 2013) and immunomodulation of the disease develops, OPN downregulation could be expected. The dynamics profile of OPN achieved suggests that it plays a role in early development of pathological changes then its role declines afterwards.

The significant association between high OPN expression and bigger granuloma size detected suggest that OPN expression is linked to Th1/Th2 response to granuloma formation as OPN production can attract inflammatory cells producing granulomas. In agreement with Morimoto et al. (2004) who stated that OPN can affect the granulomatous reaction in different model of granulomatous liver disease. Despite differences in some immunologic mechanisms and variation in size and consistency of granulomas in between *S. mansoni* and *S. japonicum*, Chen et al. (2011) reported a positive linear regression between OPN mRNA expression and granuloma size which intern accentuates the suggested role of OPN in schistosomal pathology.

A statistically highly significant variation in both liver and colon OPN intensity was found; the expression started in week7 and gradually increasing over time to peak in week 13 in liver and week 11 and 13 all together in colon. Afterwards decline in the degree of expression was recorded to reach its mild form by week 21 to 23. Finally, a highly significant variation in OPN intensity between liver and colonic tissue as moderate OPN intensity goes best with liver samples whereas mild in colonic samples. This difference may be attributed to multiple origin of OPN production highlighting the liver contribution to its production by Kupffer cells. Then again murine colonic granulomas and fibrosis were stated to be smaller as they are not downregulated as those of the liver granulomas (Cheever et al., 2002) so these data could explain why OPN expression varied between liver and colon though well detected in both samples.

Thus, our data emphasize the contribution of Osteopontin in the development of schistosomal colonic and hepatopathologic changes. And the expression profile obtained may open insights in using anti OPN during early stages of inflammation and granuloma formation to prevent the pathological damage.

LIMITATION OF THE STUDY

A larger sample size may provide a more accurate results especially regarding laboratory results. The study could not eliminate the effect of fat in diet on the liver OPN expression.

The dynamics of OPN expression and its link to pathological changes in both liver and colon may add another piece of information to help in solving the puzzle of schistosomiasis impact proposing a new prognostic and therapeutic target. This study highlights the use of OPN as a potential diagnostic marker of liver injury and the probability of using an anti OPN in early chronicity stage to prevent schistosomal subsequent pathological changes.

ETHICAL CONSIDERATION

The study was approved by the Research Ethics Committee, Faculty of Medicine, Ain Shams University. All the animal experiments were performed according to the Original article and national regulations for the Animal Ethics rules, Ain-Shams University, Cairo, Egypt.

ACKNOWLEDGEMENTS

All thanks goes to TBRI Schistosome Biological Supply Center. Special thanks to Emeritus Prof. Soheir Sayed Mohammed Mahmoud.

CONFLICT OF INTEREST

The authors declare that they have no conflict of interest.

AUTHORS CONTRIBUTION

Authors HH and NE equally contributed in the experimental animal model as well as manuscript writing, revision and approval. NR, RT, YS and SE handled the pathology and immunohistochemical part. AH managed the biochemical analysis.

REFERENCES

- Agrawal D, Chen T, Irby R, Quackenbush J, Chambers AF, Szabo M, Cantor A, Coppola D, Yeatman TJ (2002). Osteopontin identified as leadmarker of colon cancer progression, using pooled sample expression profiling. *J. Natl. Cancer Inst.* 94:513-521. <https://doi.org/10.1093/jnci/94.7.513>
- Ashour DS, Shohieb ZS, Sarhan NI (2015). Upregulation of Toll-like receptor 2 and nuclear factor-kappa B expression in experimental colonic schistosomiasis. *J. Adv. Res.* 6: 877-884. <https://doi.org/10.1016/j.jare.2014.08.004>
- Bancroft JD, Gamble M (2008). (eds). *Theory and practice of histological techniques*. Elsevier health sciences. 8th edition.
- Banfi G, Colombini A, Lombardi G, Lubkowska A (2012). Metabolic markers in sports medicine. *Adv. Clin. Chem.* 56: 2. <https://doi.org/10.1016/B978-0-12-394317-0.00015-7>
- Boissier J, Chlichlia K, Digon Y, Ruppel A, Mone H (2003). Preliminary study on sex-related inflammatory reactions in mice infected with *Schistosoma mansoni*. *Parasit. Res.* 91(2):

- 144-150. <https://doi.org/10.1007/s00436-003-0943-1>
- Boudjadi S, Bernatchez G, Beaulieu JF, Carrier JC (2013). Control of the human osteopontin promoter by ERR α in colorectal cancer. *American J. Pathol.* 183(1): 266-276. <https://doi.org/10.1016/j.ajpath.2013.03.021>
- Cabiati M, Gaggini M, Cesare MM, Caselli C, De Simone P, Filipponi F, Basta G, Gastaldelli A, Del Ry S (2017). Osteopontin in hepatocellular carcinoma: A possible biomarker for diagnosis and follow-up. *Cytokine.* 1(99):59-65. <https://doi.org/10.1016/j.cyto.2017.07.004>
- Camacho-Lobato L, Borges DR (1998) Early liver dysfunction in schistosomiasis. *J. Hepatol.* 29: 233-240. [https://doi.org/10.1016/S0168-8278\(98\)80008-1](https://doi.org/10.1016/S0168-8278(98)80008-1)
- Cheever AW, Lenzi JA, Lenzi HL, Andrade ZA (2002). Experimental models of *Schistosoma mansoni* infection. *Memórias do Instituto Oswaldo Cruz.* 97(7):917-940. <https://doi.org/10.1590/S0074-02762002000700002>
- Chen BL, Zhang GY, Wang SP, Li Q, Xu MH, Shen YM. et al (2012). The combined treatment of praziquantel with osteopontin immunoneutralization reduces liver damage in *Schistosoma japonicum*-infected mice. *Parasitology.* 139:522-9. <https://doi.org/10.1017/S0031182011002241>
- Chen BL, Zhang GY, Yuan WJ (2011). Osteopontin expression is associated with hepatopathologic changes in *Schistosoma japonicum* infected mice. *World J. Gastroenterol.* 17(46): 5075-5082. <https://doi.org/10.3748/wjg.v17.i46.5075>
- Colley DG, Secor WE (2014). Immunology of human schistosomiasis. *Parasit. Immunol.* 36(8): 347-357. <https://doi.org/10.1111/pim.12087>
- Coombes JD, Swiderska-Syn M, Dolle L, Reid D, Eksteen B, Claridge L, et al. (2015). Osteopontin neutralisation abrogates the liver progenitor cell response and fibrogenesis in mice. *Gut.* 64: 1120-31. <https://doi.org/10.1136/gutjnl-2013-306484>
- Der G, Everitt BS (2014). *A handbook of statistical graphics using SAS ODS*. CRC Press. ISBN 978-1-584-88784-3. <https://doi.org/10.1201/b17312>
- El-Asrar A, Ahmed M, Imtiaz Nawaz M, Kangave D, Siddiquei MM, Geboes K. (2012). Osteopontin and other regulators of angiogenesis and fibrogenesis in the vitreous from patients with proliferative vitreoretinal disorders. *Mediators of inflammation.* <https://doi.org/10.1155/2012/493043>
- Elmorshedy H, Bergquist R, Fayed A, Guirguis W, Abdel-Gawwad E, Eissa S, Barakat R (2020). Elimination of schistosomiasis requires multifactorial diagnostics: evidence from high-and low-prevalence areas in the Nile Delta, Egypt. *Infect. Dis. Poverty.* 9:1-3. <https://doi.org/10.1186/s40249-020-00648-9>
- Gad YZ, Ahmad NA, El-Desoky I, Arafa MM, Farag RE (2011). Colorectal schistosomiasis: Is it still endemic in delta Egypt, early in the third millennium? *Trop. Parasitol.* 1(2):108-10 <https://doi.org/10.4103/2229-5070.86948>
- Gryseels B, Polman K, Clerinx J, Kestens L (2006). Human schistosomiasis. *Lancet.* 368(9541):1106-1118. [https://doi.org/10.1016/S0140-6736\(06\)69440-3](https://doi.org/10.1016/S0140-6736(06)69440-3)
- Hams E, Aviello G, Fallon PG (2013). The *Schistosoma* granuloma: friend or foe? *Front. Immunol.* 4: 89. <https://doi.org/10.3389/fimmu.2013.00089>
- Higashiyama M, Ito T, Tanaka E, Shimada Y (2007). Prognostic significance of osteopontin expression in human gastric carcinoma. *Ann. Surg. Oncol.* 14(12):3419-27. <https://doi.org/10.1245/s10434-010-1143-8>
- Hotez PJ, Alvarado M, Basanez MG, Bolliger I, Bourne R,

- Boussinesq M, et al (2014). The global burden of disease study 2010: interpretation and implications for the neglected tropical diseases. *PLoS Negl Trop. Dis.* 8(7):2865. <https://doi.org/10.1371/journal.pntd.0002496>
- Ito T, Hashimoto Y, Tanaka E, Kan T, Tsunoda S, Sato F, Higashiyama M, Okumura T, Shimada Y (2006). An inducible short-hairpin RNA vector against osteopontin reduces metastatic potential of human esophageal squamous cell carcinoma in vitro and in vivo. *Clin. Cancer Res.* 12(4):1308-1316. <https://doi.org/10.1158/1078-0432.CCR-05-1611>
 - Kelly DJ, Chanty A, Gow RM, Zhang Y, Gilbert RE (2005). Protein kinase C β inhibition attenuates osteopontin expression, macrophage recruitment, and tubulointerstitial injury in advanced experimental diabetic nephropathy. *Journal of the American Society of Nephrology.* 16(6):1654-1660. <https://doi.org/10.1681/ASN.2004070578>
 - Lambertucci JR (2014). Revisiting the concept of hepatosplenic schistosomiasis and its challenges using traditional and new tools. *Rev. Soc. Bras. Med. Trop.* 47: 130-136. <https://doi.org/10.1590/0037-8682-0186-2013>
 - Leite LAC, Pimenta Filho AA, Fonseca CSMd, Santos BSd, Ferreira RdCdS, Montenegro SML, et al. (2013). Hemostatic Dysfunction Is Increased in Patients with Hepatosplenic Schistosomiasis Mansoni and Advanced Periportal Fibrosis. *PLoS Negl. Trop. Dis.* 7(7): e2314. <https://doi.org/10.1371/journal.pntd.0002314>
 - Lichtenberg F V (1962). Host response to eggs of *S. mansoni*. I. Granuloma formation in the unsensitized laboratory mouse. *Am. J. Pathol.* 41: 711-731.
 - Likui W, Hong W, Shuwen Z (2010). Clinical significance of the upregulated osteopontin mRNA expression in human colorectal cancer. *J. Gastrointest. Surg.* 14:74-81. <https://doi.org/10.1007/s11605-009-1035-z>
 - Mati VLT, Melo AL (2013). Current applications of oogram methodology in experimental schistosomiasis; fecundity of female *Schistosoma mansoni* and egg release in the intestine of AKR/J mice following immunomodulatory treatment with pentoxifylline. *J. Helminthol.* 87(1): 115-124. <https://doi.org/10.1017/S0022149X12000144>
 - Matsue Y, Tsutsumi M, Hayashi N, Saito T, Tsuchishima M, Toshikuni N, et al. (2015). Serum Osteopontin Predicts Degree of Hepatic Fibrosis and serves as a Biomarker in Patients with Hepatitis C Virus Infection. *PLoS ONE.* 10(3): e0118744. <https://doi.org/10.1371/journal.pone.0118744>
 - Morimoto J, Inobe M, Kimura C, Kon S, Diao H, Aoki M, et al. (2004). Osteopontin affects the persistence of beta-glucan-induced hepatic granuloma formation and tissue injury through two distinct mechanisms. *Int. Immunol.* 16: 477-88. <https://doi.org/10.1093/intimm/dxh044>
 - Naghavi M, Abajobir AA, Abbafati C, Abbas KM, Abd-Allah F, Abera SF, Aboyans V, Adetokunboh O, Afshin A, Agrawal A, Ahmadi A (2017). Global, regional, and national age-specific mortality for 264 causes of death, 1980-2016: a systematic analysis for the Global Burden of Disease Study 2016. *The Lancet.* Sep 16;390(10100):1151-210.
 - Naldini A, Leali D, Pucci A, Morena E, Carraro F, Nico B, Ribatti D, Presta M (2016). Cutting edge: IL-1 β mediates the proangiogenic activity of osteopontin-activated human monocytes. *J. Immunol.* 1;177(7):4267-70. <https://doi.org/10.4049/jimmunol.177.7.4267>
 - O'regan AW, Hayden JM, Body S, Liaw L, Mulligan N, Goetschkes M, Berman JS (2001). Abnormal pulmonary granuloma formation in osteopontin-deficient mice. *American J. Respirat. Crit. Care Med.* 164(12):2243-2247. <https://doi.org/10.1164/ajrccm.164.12.2104139>
 - Pellegrino J, Siqueira AF (1956). Técnica de perfusão para colheita de *Schistosoma mansoni* em cobaias experimentalmente infestadas. *Revista Brasileira de Malariologia e Doenças Tropicais.* 8: 589-597.
 - Pereira TA, Syn WK, Machado MV, Vidigal PV, Resende V, Voietta I, et al. (2015). Schistosome-induced cholangiocyte proliferation and osteopontin secretion correlate with fibrosis and portal hypertension in human and murine schistosomiasis mansoni. *Clin. Sci. (Lond).* 129(10):875-883. <https://doi.org/10.1042/CS20150117>
 - Pereira TA, Syn WK, Amâncio FF, Cunha PH, Caporali JF, Trindade GV, Santos ET, Souza MM, Andrade ZA, Witek RP, Secor WE (2016). Osteopontin is upregulated in human and murine acute schistosomiasis mansoni. *PLoS neglected Trop. Dis.* 10(10):e0005057. <https://doi.org/10.1371/journal.pntd.0005057>
 - Plackett RL (1983). «Karl Pearson and the Chi-Squared Test». *International Statistical Review.* International Statistical Institute (ISI). 51 (1): 59. <https://doi.org/10.2307/1402731-72>
 - Rohde F, Rimkus C, Friederichs J, Rosenberg R, Marthen C, Doll D, Holzmann B, Siewert JR, Janssen KP (2007). Expression of osteopontin, a target gene of de-regulated Wnt signaling, predicts survival in colon cancer. *Int. J. Cancer.* 121:1717-1723. <https://doi.org/10.1002/ijc.22868>
 - Sabry HA, El-Aal AA, Mahmoud NS, Nabil Y, Aziz I Z (2015). An initial indication of predisposing risk of *Schistosoma mansoni* infection for hepatocellular carcinoma. *J. Egyptian Societ. Parasitol.* 45(2): 233-240. <https://doi.org/10.12816/0017568>
 - Shang S, Plymoth A, Ge S, Feng Z, Rosen HR, Sangrajang S, et al. (2012). Identification of osteopontin as a novel marker for early hepatocellular carcinoma. *Hepatology.* 55: 483-90. <https://doi.org/10.1002/hep.24703>
 - Sherwood RA, Bomford A (2014). Assessment of hepatic function and investigation of jaundice. In *Clinical Biochemistry: Metabolic and Clinical Aspects (Third Edition)* eds William J. Marshall, Márta Lapsley, Andrew Day, Ruth Ayling Elsevier Health Sciences. 231-249. <https://doi.org/10.1016/B978-0-7020-5140-1.00013-4>
 - Tang M, Jiang Y, Jia H, Patpur BK, Yang B, Li J, Yang C. (2020). Osteopontin acts as a negative regulator of autophagy accelerating lipid accumulation during the development of nonalcoholic fatty liver disease. *Artificial Cells, Nanomed. Biotechnol.* 48(1):159-68. <https://doi.org/10.1080/21691401.2019.1699822>
 - Wang X, Lopategi A, Ge X, Lu Y, Kitamura N, Urtasun R, et al (2014). Osteopontin induces ductular reaction contributing to liver fibrosis. *Gut.* 63: 1805-1818. <https://doi.org/10.1136/gutjnl-2013-306373>
 - Warren KS, Boros DL, Hang LH, Mahmoud AAF (1975). The *Schistosoma japonicum* Egg Granuloma. *American J. Pathol.* 80(2): 279-293.
 - Wen Y, Jeong S, Xia Q, Kong X (2016). Role of osteopontin in liver diseases. *Int. J. Biolog. Sci.* 12(9): 1121. <https://doi.org/10.7150/ijbs.16445>
 - WHO - World Health Organization, Global health estimates (2015). disease burden by cause: age, sex, by country and by region; 2000-2015. www.who.int/healthinfo/global_

- [burden_disease/estimates_regional_2000_2015/en/](#)
- WHO - World Health Organization/Pan American Health (2016). Neglected infectious diseases in the Americas: success stories and innovation to reach the neediest. ISBN:978-92-75-11896-2.
 - Young DS (2001). Effects of disease on Clinical Lab. Tests, 4th ed AACC.